



PRESENTING CLINICAL SIGNS

History: Grade 2-3/6 left-sided murmur. Previously diagnosed with degenerative valve disease.

DATE

6/14/23

ECHOCARDIOGRAPHIC FINDINGS

2D, M-mode, and Doppler study.

PERFORMED BY:

Shari Reffi, CVT

INTERPRETED BY

Keith Blass, DVM,
MS, DACVIM
(Cardiology)

Left atrial size is normal. The mitral valve leaflets are mildly thickened and exhibit mild systolic prolapse. A mild to moderate jet of eccentric mitral regurgitation is present. Left ventricular dimensions are normal. Left ventricular systolic function is normal. The aorta and aortic valve appear normal, though trace aortic insufficiency is present. Right atrial and right ventricular dimensions are normal. The tricuspid valve leaflets are mildly thickened, and a mild jet of tricuspid regurgitation is present. TR velocity does not suggest the presence of pulmonary hypertension. The pulmonary artery and pulmonic valve appear normal, though trace pulmonic insufficiency is present. No shunting lesions are visualized. No pericardial effusion or cardiac masses are seen.

LA - 32.3 mm
LVIDd - 30.2 mm
LVIDs - 18.9 mm
FS - 37.4%
RA - 21.8 mm
LVOT - 1.30 m/s
RVOT - 0.70 m/s
TR - 1.72 m/s

PATIENT

Cooper Weeks

SPECIES

Canine

ASSESSMENT/RECOMMENDATIONS

Degenerative mitral and tricuspid valve disease

BREED

CKCS

This examination demonstrates no progression of Cooper's valvular diseases over the past 6 months. Given the absence of secondary cardiac chamber dilation, Cooper's valvular diseases appear to be well-compensated, and his current risk for the development of clinical signs secondary to them appears to be low.

No therapy is recommended at this stage of Cooper's valvular diseases.

SEX

A recheck echocardiogram is recommended in 6 months to monitor for disease progression.

MN

AGE

10 y

WEIGHT

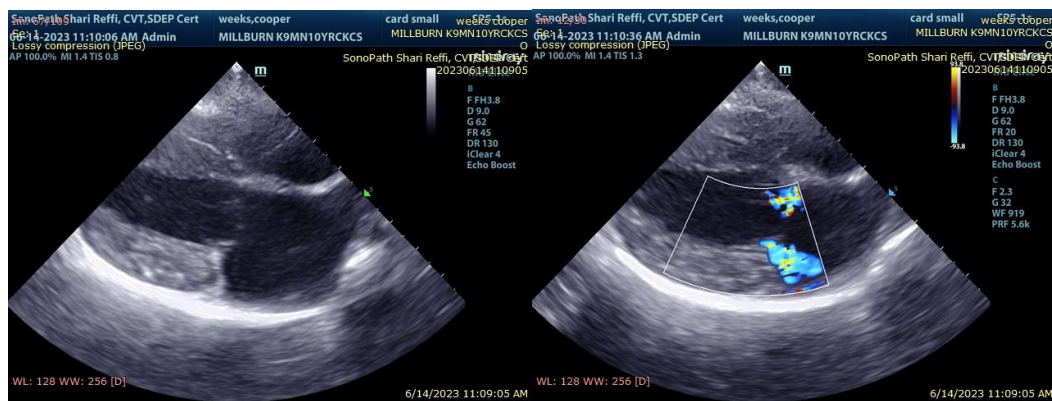
27.5 lb

HOSPITAL NAME

Millburn VH

REFERRING VET

Dr. Turowsky



The information and recommendations provided are based on the images presented by the referring veterinarian. No evaluation can be communicated regarding pathology that was not



visible in the image/video clips provided.

DATE Thank you for this referral. If the clinical or image interpretation does not parallel your findings or if I can be of any further assistance please contact me.

6/14/23

PERFORMED BY: Keith Blass, DVM, MS, DACVIM (Cardiology)
KeithBlass@gmail.com
631-804-5754

Shari Reffi, CVT

INTERPRETED BY

Keith Blass, DVM,
MS, DACVIM
(Cardiology)

PATIENT

Cooper Weeks

SPECIES

Canine

BREED

CKCS

SEX

MN

AGE

10 y

WEIGHT

27.5 lb

HOSPITAL NAME

Millburn VH

REFERRING VET

Dr. Turowsky